

Diagnosis and management of acute graft-versus-host disease

Fiona L. Dignan,^{1,2} Andrew Clark,³ Persis Amrolia,⁴ Jacqueline Cornish,⁵ Graham Jackson,⁶ Prem Mahendra,⁷ Julia J. Scarisbrick,⁸ Peter C. Taylor,⁹ Nedim Hadzic,¹⁰ Bronwen E. Shaw^{1,11} and Michael N. Potter¹ on behalf of the Haemato-oncology Task Force of the British Committee for Standards in Haematology and the British Society for Blood and Marrow Transplantation

¹Section of Haemato-oncology, The Royal Marsden NHS Foundation Trust, London, ²St John's Institute of Dermatology, St Thomas' Hospital, London, ³Bone Marrow Transplant Unit, Beatson Oncology Centre, Gartnavel Hospital, Glasgow, ⁴Department of Bone Marrow Transplantation, Great Ormond Street Hospital, London, ⁵Department of Haematology, Bristol Royal Hospital for Children, Bristol, ⁶Department of Haematology, Freeman Road Hospital, Newcastle, ⁷Department of Haematology, University Hospital Birmingham, Birmingham, ⁸Department of Haematology, University Hospital Birmingham, Birmingham, ⁹Department of Haematology, Rotherham General Hospital, Rotherham, ¹⁰Paediatric Liver Service and Institute of Liver Studies, King's College Hospital, London, and ¹¹Anthony Nolan London, UK

Summary

A joint working group established by the Haemato-oncology subgroup of the British Committee for Standards in Haematology (BCSH) and the British Society for Bone Marrow Transplantation (BSBMT) has reviewed the available literature and made recommendations for the diagnosis and management of acute graft-versus-host disease. This guideline includes recommendations for the diagnosis and grading of acute graft-versus-host disease as well as primary treatment and options for patients with steroid-refractory disease. The goal of treatment should be effective control of graft-versus-host disease while minimizing risk of toxicity and relapse.

Keywords: acute graft-versus-host disease, aGvHD, transplant, management, diagnosis.

Summary of Recommendations

- 1 An accountable transplant physician should be responsible for supervising the treatment of patients with acute graft-versus-host disease (GvHD) (1C).
- 2 Clinical criteria should define acute GvHD and not purely time post-transplant (1B).
- 3 Clinical diagnosis is appropriate if the classical constellation of symptoms is present. Biopsies may be helpful if the diagnosis is unclear but should not delay management (1A).

- 4 At diagnosis, the extent of individual organ involvement and overall grade of acute GvHD should be documented, taking into account all organ involvement, as this has prognostic significance (1A).
- 5 The modified Seattle Glucksberg criteria (Przepiorka *et al* 1995) are recommended for grading (1A).
- 6 The management of grade 1 disease should include topical therapy and optimizing levels of calcineurin inhibitors without the need for additional systemic immunosuppression (1C).
- 7 The use of systemic corticosteroids is recommended for first line therapy for grade II–IV GvHD (1A).
- 8 Two milligram/kg per day of methylprednisolone is recommended as the starting dose for patients with grades III–IV GvHD (1A).
- 9 One milligram/kg per day of methylprednisolone is recommended for patients with grade II GvHD (2B).
- 10 The use of 'nonabsorbable' steroids can be considered for acute intestinal GvHD in order to reduce the dose of systemic steroids (2B).
- 11 The following agents are suggested for use in the second line treatment of steroid-refractory acute GvHD: extracorporeal photopheresis, anti-tumour necrosis factor α antibodies, mammalian target of rapamycin (mTOR) inhibitors, mycophenolate mofetil, interleukin-2 receptor antibodies (2C).
- 12 The following agents are suggested as third line treatment options in acute steroid-refractory GvHD: alemtuzumab, pentostatin, mesenchymal stem cells and methotrexate (2C).

Introduction

Graft-versus-host disease (GvHD) remains a major complication of haematopoietic stem cell transplantation. The incidence of acute GvHD (aGvHD) is 10–80%, depending upon

Correspondence: BCSH Secretary, British Society for Haematology, 100 White Lion Street, London, N1 9PF, UK.

E-mail: bcsh@b-s-h.org.uk

First published online 26 April 2012
doi: 10.1111/j.1365-2141.2012.09129.x

© 2012 Blackwell Publishing Ltd
British Journal of Haematology, 2012, **158**, 30–45

the risk factors present (Sullivan, 2004). Corticosteroids are effective in <50% of patients (Martin *et al*, 1990). A number of novel agents have been developed and investigated, both as first line treatments and for management of steroid-refractory disease. Despite these developments, there is no consensus on the optimal strategy for managing GvHD.

A joint working group established by the Haemato-oncology subgroup of the British Committee for Standards in Haematology (BCSH) and the British Society of Blood and Marrow Transplantation (BSBMT) has reviewed the available literature and made recommendations for the diagnosis and management of GvHD. The guideline has been split into three documents, including 'Diagnosis and Management of Acute GvHD' (present guideline), 'Diagnosis and Management of Chronic GvHD' (Dignan *et al*, 2012a) and 'Organ-specific Management and Supportive Care in GvHD' (Dignan *et al*, 2012b). These guidelines are designed to be used together and to complement each other in order to provide an evidence-based approach to managing this complex disorder. The goal of treatment should be effective control of GvHD while minimizing the risk of toxicity and relapse. The prevention of aGvHD using prophylactic agents will not be included in the current document. These guidelines discuss GvHD following allogeneic transplant and will not discuss transfusion-related GvHD.

The key areas covered in 'Diagnosis and Management of Acute GvHD' and 'Diagnosis and Management of Chronic GvHD' are:

- Diagnosis
- Grading
- First line treatment
- Second line treatment
- Third line treatment
- Other agents

The key areas covered in 'Organ-specific Management and Supportive Care in GvHD' are:

- Organ-Specific Management of GvHD:
 - Cutaneous
 - Gastrointestinal
 - Genital
 - Liver
 - Ocular
 - Oral
 - Pulmonary
- Infection prophylaxis in GvHD
- Vaccinations
- Management of complications associated with long-term steroid use

Methodology

The production of these guidelines involved the following steps:

- Establishment of a working group comprising experts in the field of allogeneic transplantation followed by literature review to 17 June 2011 including Medline, internet searches and major conference reports.
- Development of key recommendations based on randomized, controlled trial evidence. Due to the paucity of randomized studies some recommendations are based on literature review and a consensus of expert opinion.
- The GRADE nomenclature was used to evaluate levels of evidence and to assess the strength of recommendations. The GRADE criteria are specified in the BCSH guideline pack and the GRADE working group website (see Appendix I). Further information is available from the following websites:
 - http://www.bcshguidelines.com/4_HAEMATOLOGY_GUIDELINES.html
 - <http://www.gradeworkinggroup.org/index.htm>
- Review by the BCSH committees, BSBMT executive committee, the UK Photopheresis Society and the UK Paediatric Bone Marrow Transplant Group.
- Review by sounding board of the British Society for Haematology (BSH) and allogeneic transplant centres in the UK.

Children

Recommendations in these guidelines are applicable to adults and children unless otherwise specified. The doses in the guidelines are for adults and the equivalent paediatric doses would need to be calculated according to the unit policy of the paediatric transplant centre. The following issues are particularly important in paediatric practice:

- A substantial number of children undergo transplants for non-malignant disorders and will not benefit from the graft-versus-malignancy effect. This may have implications for the choice of GvHD therapy.
- There may be a variety of co-morbidities due to the underlying disease which may alter the appearance of GvHD.
- The toxicities of treatment may be different in a growing child with a developing organ system and these side effects should be considered when choosing a treatment option

Diagnosis

The diagnosis of aGvHD is predominantly based on clinical findings and is often one of exclusion. Any form of aGvHD can be associated with culture-negative fever. The skin is the organ most commonly involved at the onset of aGvHD followed by gastrointestinal (GI) tract and liver (Martin *et al*, 1990). Skin GvHD typically causes a maculopapular rash, which usually starts on the palms and soles but may commence in any part of the skin. It then usually spreads to

include the rest of the body. In the most severe forms a reaction similar to toxic epidermal necrolysis may occur, with widespread skin involvement and mucocutaneous ulceration and bullae (Vogelsang *et al*, 2003). The differential diagnosis includes drug reactions, viral exanthems, engraftment syndrome and effects of chemotherapy or radiation. The distribution of the rash over the face, palms and soles is more common in aGvHD compared to drug rashes and the association with hyperbilirubinaemia and diarrhoea also makes GvHD more likely (Byun *et al*, 2011).

Cutaneous biopsy may be important, particularly in the absence of the classical constellation of symptoms. Histological features include apoptosis at base of epidermal rete pegs, dyskeratosis, exocytosis of lymphocytes, satellite lymphocytes adjacent to dyskeratotic epidermal keratinocytes and perivascular lymphocytic infiltration in the dermis (Ferrara & Deeg, 1991; Goker *et al*, 2001). Cutaneous biopsy was not found to be useful in predicting severity of disease: a retrospective study of 51 skin biopsies showed that there was poor correlation between the clinical severity of skin rash and biopsy findings and concluded that skin biopsies may have a limited role in the management of aGvHD (Zhou *et al*, 2000). A decision analysis (Firoz *et al*, 2006) also concluded that, in the allogeneic stem cell transplantation group, the best outcomes would be obtained with treatment of GvHD and no skin biopsy. More recently, elafin has been found to be over-expressed in GvHD skin biopsies. Plasma levels of elafin have been found to be significantly higher at the onset of skin GvHD, and correlate with severe GvHD, with a greater risk of death relative to other known risk factors (hazard ratio, 1.78) and may have prognostic value as a biomarker of skin GvHD (Paczesy *et al*, 2010). Carefully designed prospective studies with blinded pathological review and careful assessment of clinical outcomes are necessary to confirm the test characteristics of skin biopsy in aGvHD. Biopsies may be helpful where the diagnosis is unclear but should not delay management in patients with classical clinical features of aGvHD.

GI aGvHD typically leads to secretory diarrhoea but nausea, vomiting, anorexia, weight loss and abdominal pain can also occur. Diarrhoea can be copious and, in severe aGvHD, bleeding may result from mucosal ulceration (Nevo *et al*, 1999) and ileus may ensue. The differential diagnosis includes the side effects of chemotherapy or other drugs and infection of the GI tract. Patchy involvement can lead to a normal appearance on endoscopy (Ponec *et al*, 1999) but a positive correlation has been demonstrated between endoscopic findings from intestinal mucosa and histological grading (Cruz-Correa *et al*, 2002). Biopsies taken at endoscopy may show patchy ulcerations, apoptotic bodies at crypt bases, crypt ulceration and flattening of surface epithelium (Snover *et al*, 1985). In patients with symptoms suggestive of upper GI involvement with aGvHD, upper GI endoscopy as well as lower endoscopic biopsy may be helpful (Roy *et al*, 1991). In patients who underwent both upper and lower GI investiga-

tion, however, biopsy of the rectosigmoid was found to be the most informative in a retrospective study of 112 patients (Ross *et al*, 2008). Imaging of the GI tract may reveal luminal dilatation, thickening of the small bowel wall or air or fluid levels suggestive of an ileus (Vogelsang *et al*, 2003). Positron emission tomography may also be helpful in the assessment of intestinal GvHD (Stelljes *et al*, 2008). Biopsies may be helpful where the diagnosis is unclear but should not delay management in patients with classical clinical features of aGvHD. Biopsies may be particularly helpful to exclude alternative or co-existing GI pathologies or in patients who do not respond quickly to first line treatment.

Liver aGvHD typically presents with jaundice and a cholestatic pattern of liver injury including elevated conjugated bilirubin, alkaline phosphatase and gamma-glutamyl-transpeptidase. A hepatic picture with elevation of alanine aminotransferase has been described in aGvHD occurring after donor lymphocyte infusion as well as in some patients with acute and chronic GvHD (Strasser *et al*, 2000; Fujii *et al*, 2001; Akpek *et al*, 2002). This pattern of liver function derangement is particularly variable in children. Total bile acids and cholesterol in the serum are also elevated, while coagulopathy and hyperammonaemia develop in more severe cases. Serum lipoprotein X, a nonspecific marker of persistent cholestasis, can become positive during evolution to chronic GvHD (Zidan *et al*, 2008). Additional clinical signs of liver aGvHD are painful hepatomegaly, dark urine/pale stools and fluid retention. Nonspecific symptoms, such as fever, lack of appetite and nausea, are common. Pruritus can follow in more severe forms. The differential diagnosis is wide and includes veno-occlusive disease of the liver, viral infections, drug toxicity and sepsis.

Histopathological findings can include endothelialitis, lymphocytic infiltration of the portal areas, pericholangitis and bile-duct destruction (Snover *et al*, 1984). Duarte *et al* (2005) also suggested that high levels of lobular inflammation and a low level of hepatocyte ballooning were independent favourable prognostic factors for non-relapse mortality. Iron overload, frequently described in the liver biopsies, is often a sequel of previous blood product requirements rather than a pathogenic element in aGvHD, but could represent an adverse prognostic factor (Oshrine *et al*, 2011). In practice, it is often difficult to perform liver biopsies due to the bleeding risks associated with thrombocytopenia (Ferrara *et al*, 2009). A recent paediatric study reported complications following 5 out of 18 liver biopsies in haematopoietic stem cell transplant patients, including four patients who had undergone transjugular biopsy (Oshrine *et al*, 2011).

Historically, aGvHD has been described as occurring before 100 d post-transplant, with hyperacute GvHD occurring before neutrophil engraftment. The revised National Institute for Health (NIH) criteria now define classic aGvHD as occurring before 100 d and late onset aGvHD which has typical signs and symptoms but occurs after 100 d (Filipovich *et al*, 2005). An overlap syndrome has also been described where

patients have features of both acute and chronic GvHD. Both late onset and overlap syndrome arise more frequently after reduced-intensity conditioning (Filipovich *et al*, 2005).

Recommendations

- **An accountable transplant physician should be responsible for supervising the treatment of patients with acute GvHD (1C).**
- **Clinical criteria should define acute GvHD and not purely time post-transplant (1B).**
- **Clinical diagnosis is appropriate if the classical constellation of symptoms is present. Biopsies may be helpful if diagnosis is unclear but should not delay management (1A).**

Grading

The first grading criteria for aGvHD were published Glucksberg *et al* (1974). These criteria include a stage between 1 and 4 for each organ involved, which are then combined to give an overall grade, from I to IV. A subsequent grading system was devised following a consensus conference in 1994, which removed the need to assess clinical performance (Przepiorka *et al*, 1995; reviewed in Devergie, 2008). These grading systems include the percentage of skin involvement. The percentage of body surface area involved can be calculated using the 'rule of nines' (Hettiaratchy & Papini, 2004). A further staging system was defined by the International Bone Marrow Transplant Registry (IBMTR), which classified severity from A to D based on transplant outcome (Rowlings *et al*, 1997).

A prospective study was undertaken to compare the Glucksberg criteria with those from the IBMTR (Cahn *et al*, 2005). This study failed to show a clear benefit of one system

over the other. There was less physician bias in assigning grades with the IBMTR scoring system but the Glucksberg system was better at predicting early survival (Cahn *et al*, 2005). In practice, most centres in the United Kingdom still use the modified Glucksberg criteria based on the outcome of the consensus conference in 1994 because data collection for the European Bone Marrow Transplant (EBMT) registry is based on this system.

The grade of aGvHD has been shown to correlate with overall survival. The Chronic Leukaemia Working Group of the EBMT reviewed 1294 patients receiving an allogeneic transplant for chronic myeloid leukaemia (Gratwohl *et al*, 1995). The transplant-related mortality (TRM) for grades 0–IV aGvHD was 28%, 27%, 43%, 68% and 92%, respectively. A distinct difference in prognosis was noted between grades 0–1 and grades II–IV (Gratwohl *et al*, 1995).

Recommendations

- **At diagnosis, the extent of individual organ involvement and overall grade of aGvHD should be documented, taking into account all organ involvement, as this has prognostic significance (1A).**
- **The modified Seattle Glucksberg criteria (Przepiorka *et al*, 1995) are recommended for grading (1A).**

Management of acute GvHD

Overview

There are few reports of randomized controlled trials of the management of aGvHD and patients should be included in trial protocols wherever possible. Second and third line options are likely to be determined on availability of treatments, financial considerations and individual patient and physician preferences.

Table I. Suitable topical steroids for use in acute GvHD.

Steroid strength	Very potent e.g. Dermovate	Potent e.g. Betnovate	Moderately potent e.g. Eumovate	Mildly potent e.g. 1% Hydrocortisone
Face	Should generally be avoided	Twice daily 4–12 weeks	Twice daily 6–12 months	Twice daily Long term use acceptable
Body	Twice daily 4–12 weeks	Twice daily Long term therapy may be appropriate		
Palms and soles	Twice daily May be used under occlusion to enhance efficacy. Long term therapy may be appropriate	Twice daily Long term therapy may be appropriate		

Generally a lower steroid usage is recommended in children.

Dermatology supervision is advised when using potent steroids on the face.

Side effects: prolonged use of topical steroids can thin skin and may cause erythema, striae and dyspigmentation. If more than 50 g of very potent steroid is used per week, sufficient steroid may be absorbed through the skin to result in adrenal gland suppression or Cushingoid features. Occlusion of steroids will enhance absorption and it is possible that larger amounts of weaker steroids may have the same effect.

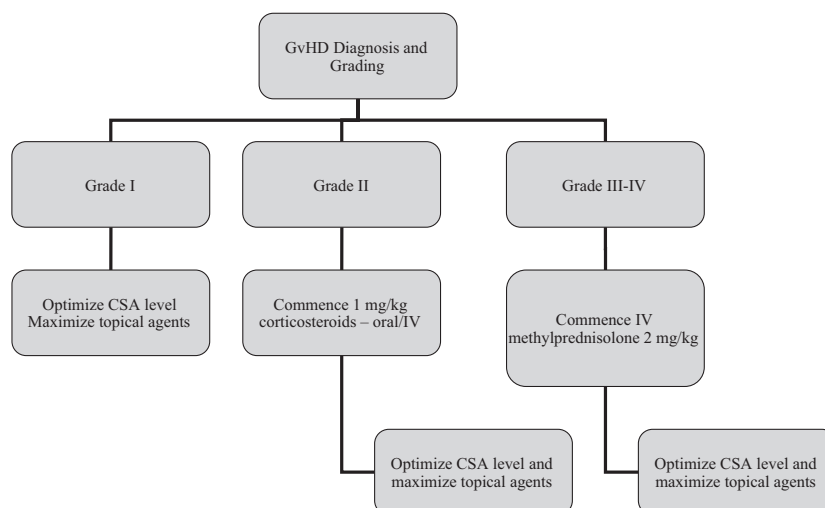


Fig 1. Treatment algorithm summarizing initial treatment of aGvHD. CSA, ciclosporin; GvHD, graft-versus-host disease.

Management of grade I disease

Patients with grade I disease are not likely to require systemic treatment. Cutaneous aGvHD may respond to topical steroid creams. Suitable strengths of topical steroids are detailed in Table I. Antihistamines may be helpful in patients with pruritis. In resistant grade I aGvHD, topical tacrolimus may also be useful although this is not a licensed indication. Adults should commence on 0.1% tacrolimus until resolution. If skin flares on stopping, 0.03% tacrolimus may be of benefit to aid weaning. 0.03% tacrolimus may be used in children aged 2–15 years. Patients should be reviewed frequently for other organ manifestations of GvHD and worsening of skin rash.

Calcineurin inhibitors are commonly used in the prophylaxis of GvHD. In patients where levels are sub-therapeutic the dose should be adjusted to ensure a therapeutic level.

Recommendation

- **The management of grade I disease should include topical therapy and optimizing levels of calcineurin inhibitors without the need for additional systemic immunosuppression (1C).**

First line treatment of grade II–IV disease

An algorithm summarizing first line treatment of aGvHD is shown in Fig 1.

Calcineurin inhibitors

Patients with grade II–IV disease are likely to require additional systemic agents to achieve a response. As in the management of grade I disease, in patients who are already

receiving calcineurin inhibitors, the dose should be adjusted to ensure a therapeutic level. In patients who are no longer receiving calcineurin inhibitors, physicians may consider restarting these agents at a therapeutic dose. In those already receiving ciclosporin, switching to tacrolimus was only found to be helpful in those patients with neurotoxicity (Furlong *et al*, 2000).

Corticosteroids

Corticosteroids have been used as the standard first line treatment for aGvHD for several decades. Their effect is likely to be due to lympholytic effects and anti-inflammatory properties (Deeg, 2007). Two early studies assessed response to corticosteroids in patients with grade II–IV GvHD (Martin *et al*, 1990; Weisdorf *et al*, 1990). Martin *et al* (1990) reported overall complete or partial responses in 44% of patients. Improvement rates were 43% for skin disease, 35% for evaluable liver disease and 50% for evaluable gut disease. Weisdorf *et al* (1990) reported a complete and continued resolution of aGvHD in 41% of patients after a median of 21 d of corticosteroids. MacMillan *et al* (2002a) reported a retrospective study of 443 patients who received prednisolone 60 mg/m² for 14 d followed by an 8-week taper. A complete response was observed in 35% of patients and a partial response in 20% of patients (MacMillan *et al*, 2002a). Corticosteroids are also the mainstay of treatment for patients with hyperacute GvHD (Deeg, 2007; Saliba *et al*, 2007).

It has also been shown that TRM is higher in patients who do not respond to steroids. Weisdorf *et al* (1990) reported a 5-year survival of 51% for steroid responders compared to 32% for steroid non-responders ($P = 0.004$). A similar increase in TRM was reported by Martin *et al* (1990) in those patients who did not achieve a complete response to steroids. In addition, an early response seems to be indicative

of improved long-term outcome. Van Lint *et al* (2006) reported a higher TRM and worse survival in those that had not responded after 5 d of methylprednisolone.

There is no consensus on the optimal dose and duration of steroid therapy due to the paucity of available literature. Van Lint *et al* (2006) suggested that 5 d of steroid therapy is sufficient to identify those patients who are responding to treatment and who may be able to start tapering their dose while Cragg *et al* (2000) continued treatment for 7 d. An IBMTR survey confirmed that most centres considered patients to be steroid-refractory after 5 d of treatment (Hsu *et al*, 2001). Similarly, this survey demonstrated that most centres used 2 mg/kg per day of methylprednisolone to be the standard primary dose. In general, intestinal and liver aGvHD require more prolonged steroid therapy than skin disease although response times vary significantly between patients (Deeg, 2007).

A recent report retrospectively compared a dose of 1 mg/kg per day (prednisolone-equivalent dose) to 2 mg/kg per day of (prednisolone-equivalent dose) and found no difference in patient outcomes in those with grade I/II disease. Definitive conclusions could not be drawn for those patients with grade III or IV disease due to the small numbers in this group (Mielcarek *et al*, 2009).

One prospective randomized trial compared a short *versus* long prednisolone taper. Patients in the long taper group achieved resolution of aGvHD after a median of 30 d of therapy compared to 42 d in the short taper group. There was no difference in survival, incidence of chronic GVHD or steroid-related complications between the two groups (Hings *et al*, 1993).

A prospective, randomized trial comparing 2 mg/kg per day of methylprednisolone with 10 mg/kg per day of methylprednisolone showed no advantage of high-dose steroids. The transplant mortality was 30% in both groups (Van Lint *et al*, 1998). The use of methylprednisolone at doses higher than 2 mg/kg per day is not routinely recommended and would be at the discretion of the treating physician.

'Nonabsorbable' steroids. Budesonide and beclomethasone have both been used in the treatment of GI GvHD. The role of nonabsorbable steroids has recently been summarized (reviewed in Ibrahim *et al*, 2009). Budesonide was used in combination with systemic corticosteroids in 22 patients with acute intestinal GvHD. A response rate of 70% was reported compared to 33% in an historical control group ($P < 0.01$) (Bertz *et al*, 1999). There have been two subsequent randomized placebo controlled studies of beclomethasone dipropionate and systemic corticosteroids compared to systemic corticosteroids alone. McDonald *et al* (1998) reported a significantly better response in patients who received beclomethasone dipropionate and systemic corticosteroids compared to systemic corticosteroids alone (McDonald *et al*, 1998). The second trial showed a cumulative rate of GvHD-treatment failure of 31% for the combination arm compared to 48% for the control arm ($P = 0.12$) (Hockenbery *et al*,

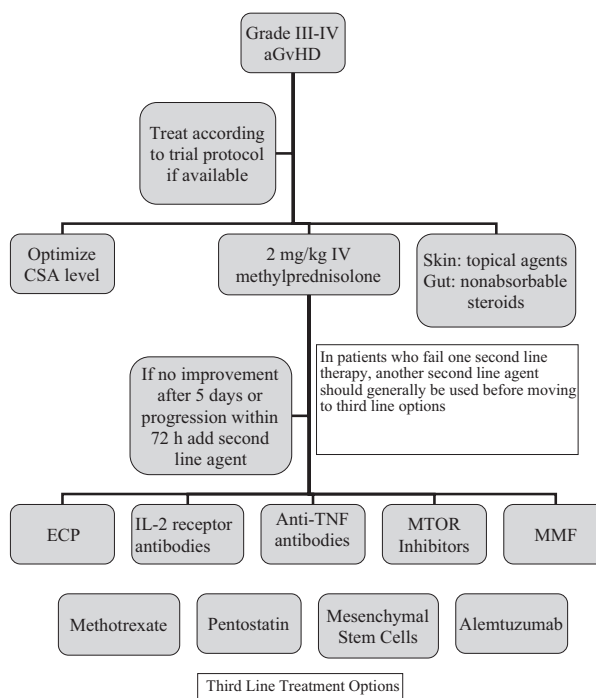


Fig 2. Treatment algorithm for Grade III–IV GvHD. ECP, extracorporeal photopheresis; IL-2, interleukin 2; TNF, tumour necrosis factor; MTOR, mammalian target of rapamycin; MMF, mycophenolate mofetil; CSA, ciclosporin; GvHD, graft-versus-host disease.

2007). This study and two others demonstrated the potential of nonabsorbable steroids to reduce the dose of systemic steroids (Bertz *et al*, 1999; Iyer *et al*, 2005). Nonabsorbable steroids may be beneficial in providing an increase in response and a steroid-sparing effect in patients with aGvHD. The authors recognize that although the term 'nonabsorbable' is widely used it is possible that a small amount of the drug may be systemically absorbed.

Recommendations

- **The use of systemic corticosteroids is recommended for first line therapy for grade II–IV GvHD (1A).**
- **Two milligram/kg per day of methylprednisolone is recommended as the starting dose for patients with grades III–IV GvHD (1A).**
- **One milligram/kg per day of methylprednisolone is recommended for patients with grade II GvHD (2B).**
- **The use of 'nonabsorbable' steroids can be considered for acute intestinal GvHD in order to reduce the dose of systemic steroids (2B).**

Second line treatment

The addition of second line agents can be considered in patients who have failed to respond despite 2 mg/kg of IV methylprednisolone in conjunction with a calcineurin inhibi-

tor for 5 d or progressive symptoms after 72 h (Deeg, 2007). Unfortunately, the available evidence for efficacy of individual agents is often derived from small trials and is frequently contradictory. Second line options may include extracorporeal photopheresis (ECP), mycophenolate mofetil (MMF), anti-tumour necrosis factor α (anti-TNF) antibodies or mammalian target of rapamycin (mTOR) inhibitors. An algorithm detailing the second line treatment of grade III–IV GvHD is shown in Fig 2. Patients who fail one-second line agent should generally try another second line agent before moving on to third line options.

Extracorporeal photopheresis

ECP is a cell-based immune-modulatory therapy that offers a different therapeutic approach. ECP involves processing up to 15% of the patients total blood volume per cycle, isolating a buffy coat (approx 5×10^9 leucocytes) and adding 8-methoxypsoralen followed by ultraviolet-A (UVA) irradiation before it is returned to the patient. The mode of action of ECP in GvHD is the focus of active research and may be multifactorial in nature (reviewed in Marshall, 2006). ECP induces apoptosis of all leucocytes (including activated T-cells) within 24 h of return. The reinfusion of these cells and subsequent phagocytosis by antigen presenting cells (APCs) may regulate immune homeostasis through modulation of cytokine production and tolerance induction of APCs (Bladon & Taylor, 2006; Perritt, 2006).

There are fewer reports detailing the role of ECP in aGvHD compared to chronic GvHD. The initial reports included small patient numbers but did suggest efficacy of ECP in the acute setting (Smith *et al*, 1998; reviewed in Dall'Amico & Messina, 2002). A retrospective series of 23 patients with acute steroid-refractory GvHD reported a complete response rate of 52% although no patients with grade IV GvHD had a complete response (Perfetti *et al*, 2008). A trend for improved survival was seen in grade III/IV GvHD compared to matched controls (38% vs 16%; $P = 0.08$) (Perfetti *et al*, 2008). The largest published series to date was a Phase 2 prospective study, which included 59 patients with steroid-refractory or steroid-dependent GvHD treated with two consecutive ECP treatments every week (Greinix *et al*, 2006). Complete responses were reported in 82% of patients with cutaneous involvement, 61% of liver involvement and 61% with gut involvement (Greinix *et al*, 2006). At 4 years, TRM was 36%. The use of ECP in the treatment of aGvHD in the UK has been reported by Das-Gupta *et al* (2011). In a series of 19 patients with steroid-refractory aGvHD, 11 patients showed a clinical response including 5/10 with grade IV GvHD (Das-Gupta *et al*, 2011).

Positive results have also been reported in children treated with ECP. Perotti *et al* (2010) reported a response rate of 68% in 50 children treated with ECP for aGvHD. The standard UVAR XTS™ (Therakos, Ascot, UK) machine is only suitable for children over 40 kg in weight although the newer

CELLEX™ (Therakos, Ascot, UK) machine is now available, which allows treatment of patients < 40 kg.

ECP has an excellent safety profile. The side effects appear to be mild and include hypotension, fevers and reduced haemoglobin level (Greinix *et al*, 1998; Perotti *et al*, 1999). There are no reports of increased infection risk or disease relapse. An indwelling catheter is required in patients with poor venous access. At present, access to ECP for aGvHD in the UK is generally limited to those centres where ECP is available on site as patients are often too unwell to travel for treatment. The optimal treatment schedule and duration of treatment has yet to be established. Das-Gupta *et al* (2011) reported a regimen of weekly cycles for a minimum of 8 weeks continued until maximal response or complete response seen.

Anti-TNF antibodies

Several studies have investigated the role of blocking the inflammatory cytokine tumour necrosis factor α (TNF α). TNF α is involved in the pathophysiology of GvHD by activating APCs, recruiting effector cells and causing direct tissue damage (Reddy & Ferrara, 2003). Earlier animal models had suggested that TNF played a major role in aGvHD of GI tract and skin (Hattori *et al*, 1998). Reports have investigated both the role of infliximab and etanercept.

Infliximab is an anti-TNF α monoclonal antibody. Several small case series suggested a possible benefit of infliximab in the treatment of steroid-refractory GvHD (Hervé *et al*, 1992; Kobbe *et al*, 2001; Couriel *et al*, 2004; Patriarca *et al*, 2004). There are also reports of an increased risk of infection in patients treated with infliximab (Marty *et al*, 2003). In a larger study of 52 patients (71% of whom had grade III/IV GvHD), 15% achieved a complete response with infliximab as salvage therapy (Pidala *et al*, 2009). In addition, a Phase 3 study of 63 patients comparing infliximab plus corticosteroids to corticosteroids alone in aGvHD did not show any improvement in response rate or overall survival in patients with newly diagnosed aGvHD (Couriel *et al*, 2009).

Etanercept is a soluble dimeric TNF α receptor 2, which renders TNF α inactive by competing for binding sites (Sieper & Van Den Brande, 2005). The drug is administered subcutaneously and has a good side effect profile (Sieper & Van Den Brande, 2005). Etanercept has been used in several studies in the primary treatment of aGvHD. A pilot study reported a 75% response rate in 20 patients with grade II/III aGvHD treated with etanercept and methylprednisolone (Uberti *et al*, 2005). A further Phase 2 study was reported by the same group comparing etanercept plus methylprednisolone in 61 patients (20 of whom had been included in the pilot study) compared to a contemporaneous group of 99 patients who received steroids alone for initial treatment of aGvHD (Levine *et al*, 2008). Patients treated with etanercept were more likely to achieve a complete response than those treated with steroids alone (69% vs 33%, $P < 0.001$) (Levine *et al*, 2008). Busca *et al* (2007) reported a response in 6/13

patients with refractory gut GvHD. Both of these studies suggested that the GI tract was particularly sensitive to TNF blockade. The infection rate was not significantly different between the two populations. Two-thirds of the patients had grade II disease.

Sirolimus (Rapamycin)

Sirolimus (Rapamycin) exerts its immunosuppressive effect through inhibition of mTOR. In a pilot trial, Benito *et al* (2001) treated 21 patients with steroid-refractory grade III/IV GvHD with sirolimus and reported response rates of 57%. The drug was discontinued in 10 patients due to lack of improvement in GvHD, myelosuppression or seizures. Five patients developed haemolytic uraemic syndrome, particularly when sirolimus was combined with calcineurin inhibitors, although the incidence of this complication in the absence of calcineurin inhibitors is very low (Benito *et al*, 2001). Similar response rates were observed in a retrospective study of 22 patients and in a recent report of 34 patients treated with sirolimus in combination with corticosteroids (Ghez *et al*, 2009; Hoda *et al*, 2010). There is also one study of 32 patients using sirolimus as primary treatment. Durable complete remissions were reported in 16 patients (Pidala *et al*, 2011).

Sirolimus may be helpful as a second line treatment option in acute GvHD. In view of the risk of haemolytic uraemic syndrome and hyperlipidaemia, mTOR inhibitors should be used with caution in combination with calcineurin inhibitors. mTOR inhibitors also have a number of other drug interactions and a dose reduction may be required when used in combination with certain drugs including all azole antifungal agents. When used in combination with azoles, the initial dose of sirolimus should be reduced by 40–50%. Regular monitoring of drug levels is recommended to avoid toxicities. Sirolimus has a half-life of about 70 h so daily levels are not required and monitoring drug levels 2–3 times per week, even after dose modification, is recommended. A sirolimus level of 4–8 ng/ml is recommended (Wolff *et al*, 2011). The lipid profile must be monitored on a monthly basis during treatment with mTOR inhibitors. Lipid lowering medication may be required. Intravenous preparations of alternative mTOR inhibitors have been used in acute GvHD but small numbers of patients and high toxicities prevent any recommendations on their use.

Mycophenolate mofetil

MMF is the 2-(4-morpholino) ethyl ester of mycophenolic acid (MPA). MMF is rapidly absorbed following oral administration and hydrolysed to MPA. MPA blocks the *de novo* pathway of purine synthesis in lymphocytes by selectively and reversibly inhibiting inosine monophosphate dehydrogenase (Allison & Eugui, 2000). Several small series have suggested a role of MMF in the management of refractory aGvHD as a steroid-sparing agent (Basara *et al*, 2001; Krejci

et al, 2005; Takami *et al*, 2006; Furlong *et al*, 2009). One study reported a response in a small group of patients but noted a high level of life-threatening infectious complications (Onishi *et al*, 2010).

In one arm of a randomized Phase 2 study MMF was administered with corticosteroids and compared to etanercept, pentostatin and denileukin diftitox in the initial management of aGvHD. Patients treated with MMF had highest day 28 complete response rates, overall survival (64%) and lowest infection rates compared to the other agents (Alousi *et al*, 2009). These results should be interpreted with caution as the patients who received the other agents had already failed prophylaxis with MMF so may have represented a higher risk group. In addition, it should be noted that this series was not powered to compare across the study arms and that 68% of patients had grade I/II GvHD.

Interleukin 2 receptor antibodies

The interleukin-2 (IL-2) receptor alpha subunit (CD25) is predominantly expressed on activated T lymphocytes and has been a particular target for monoclonal antibody treatment for GvHD. Daclizumab is a humanized immunoglobulin G1 monoclonal antibody that binds to the alpha subunit of the high-affinity IL-2 receptor and inhibits IL-2 binding. Several studies reported promising results in steroid-refractory patients but a randomized controlled trial using daclizumab with corticosteroids as upfront therapy (Lee *et al*, 2004) showed significantly worse survival compared to corticosteroids alone (Anasetti *et al*, 1994; Przepiorcka *et al*, 2000; Lee *et al*, 2004; Bordigoni *et al*, 2006). Daclizumab is no longer commercially available and therefore cannot be recommended for use in aGvHD.

Other drugs targeting the CD25 subunit have been developed. Denileukin diftitox links amino acids of the diphtheria toxin to amino acids of IL-2 in an attempt to enhance therapeutic efficacy. Two small studies showed promising results in steroid-refractory disease (Ho *et al*, 2004; Shaughnessy *et al*, 2005) but this agent is no longer available for use in the UK.

Other IL-2 receptor antibodies have been used. The use of inolimomab, a murine anti-IL-2R was retrospectively evaluated 85 patients with steroid-refractory aGvHD (Bay *et al*, 2005). The total response rate was 63% and overall survival at a median follow-up of 20 months was 26%. A further retrospective study of 40 patients reported a 58% response rate with higher responses in those without GI disease (Piñana *et al*, 2006).

Basiliximab is a chimeric IL-2 receptor antagonist. A small Phase 1 study of 17 patients reported a 71% response rate in patients with steroid-refractory GvHD and 53% survival at a median of 157 d post-transplant (Massenkeil *et al*, 2002). A prospective Phase 2 study of 23 patients reported an overall response rate of 82.5% (Schmidt-Hieber *et al*, 2005). Several other small studies have reported similar efficacy (Funke *et al*, 2006; Wang *et al*, 2008; Liu *et al*, 2009). A larger study

recently reported a response in 46/53 patients with steroid-refractory aGvHD. Twenty eight patients were alive at a median follow-up of 16 months (Wang *et al*, 2011a).

Rao *et al* (2009) reported on 22 children who received daclizumab in combination with infliximab for steroid-refractory GvHD; 19/22 patients responded. Survival at a median follow up of 31 months was 68% and there were only two infection-related deaths (Rao *et al*, 2009). A Phase 2 study using daclizumab in combination with etanercept in 21 patients reported a clinical response in 14 patients but 11 died of infection-related complications (Wolff *et al*, 2005). Srinivasan *et al* (2004) used daclizumab [alone or with infliximab/antithymocyte globulin (ATG)] with comprehensive infection prophylaxis in 12 patients and showed improved survival compared to an historical control group. A recent study treated 17 steroid-refractory aGvHD patients with combination daclizumab and infliximab; clinical response was observed in 47% of patients but all died at a median of 35 d from initiation of treatment (Rager *et al*, 2011). As daclizumab is no longer commercially available this combination cannot be recommended at present.

Recommendation

- **The following agents are suggested for use in the second line treatment of steroid-refractory acute GvHD: extracorporeal photopheresis, anti-tumour necrosis factor antibodies, mammalian target of rapamycin (mTOR) inhibitors, mycophenolate mofetil, interleukin-2 receptor antibodies (2C).**

Third line treatment

A number of other agents have been investigated for the treatment of steroid-refractory disease. In patients who fail a second line treatment option another second line option should generally be considered before moving to a third line treatment option. Some agents may be used in combination but there is little data to support this approach. The agents that may be considered for third line treatment options are discussed below and shown in Fig 2. These agents are considered to be third line options as there is less evidence available for their use. The authors acknowledge that some of these agents have not been studied in the context of third line treatment of acute GvHD.

Mesenchymal stem cells

Mesenchymal (stromal) stem cells (MSCs) are a population of undifferentiated pluripotent stem cells that modulate immune and inflammatory response and facilitate repair of connective tissues (Pittenger *et al*, 1999; Majumdar *et al*, 2000). Le Blanc *et al* (2004) were the first to report the efficacy of MSCs for the treatment of aGvHD. The same group subsequently undertook a Phase 2 study of MSCs in patients with refractory GvHD (Le Blanc *et al*, 2008). This report

included 55 patients (25 children, 30 adults) with steroid-resistant, severe aGvHD. Thirty patients had a complete response and nine showed improvement. Overall survival at 2 years post-transplant was 53% in complete responders compared to 16% in those who did not respond (Le Blanc *et al*, 2008). There were no significant adverse events. An encouraging report by Karlsson *et al* (2008) suggests that MSCs have little effect on T-cell responses to Epstein-Barr virus and cytomegalovirus (CMV), despite their strong immunosuppressive effects on alloreactive T-cells.

Prochymal[®] (Genzyme, Cambridge, UK) MSCs have been used as part of a compassionate use programme. In 12 children with grade III or IV gut GvHD a complete response was seen in seven patients and 5/12 were alive after a median follow-up of 611 d (Prasad *et al*, 2011). The same commercially generated MSCs have recently been used in a multicentre randomized controlled trial and reported in abstract form (Martin *et al*, 2010). One hundred and sixty-three patients received MSCs and 81 received placebo. Although this study did not show improved complete response rates overall in steroid-refractory aGvHD compared to the control arm, patients with steroid-refractory gut and liver aGvHD showed significantly improved response rates (82% and 76%, respectively) (Martin *et al*, 2010). Furthermore, it should be noted that not all sources of MSCs are equivalent.

A recent report used MSCs for the primary treatment of aGvHD in combination with corticosteroids (Kebriaei *et al*, 2009). Thirty-one evaluable patients were included and randomized to receive a dose of either 2 or 8 × 10⁶ MSCs/kg. Seventy-seven percent of patients had a complete response rate and 16% had a partial response rate. There were no differences in safety or efficacy between the two groups (Kebriaei *et al*, 2009). Some success has also been reported using MSCs expanded *in vitro* with human serum (Pérez-Simon *et al*, 2011). This study included 10 adult patients with acute refractory GvHD and demonstrated a complete response in one patient, a partial response in six patients and no response in the remaining three patients.

MSCs are currently available in the UK for paediatric patients with steroid-refractory aGvHD as part of the Prochymal[®] compassionate use programme from Genzyme. In addition, for both adults and children MSCs may be available from Imperial College (Professor Francesco Dazzi). A randomized study using MSC in upfront therapy of grade 3–4 aGvHD is also planned. MSCs are a promising treatment in the management of acute GvHD. At present, the authors suggest that MSCs may be considered as a third line treatment option but recognize that this is an area of active research and that MSCs may have a greater role in the management of aGvHD in the future.

Alemtuzumab

Alemtuzumab (Campath 1H) is a humanized, unconjugated IgG1 kappa monoclonal antibody that is specific for CD52

receptors present on mature T and B lymphocytes, monocytes, monocyte-derived dendritic cells, macrophages and eosinophils (Hale, 2001). Several case reports suggested that alemtuzumab might be helpful in the management of aGvHD (Varadi *et al*, 1996; Carella *et al*, 2004; Wandroo *et al*, 2004). In a prospective study, 18 patients with steroid-refractory aGvHD received alemtuzumab 10 mg subcutaneously once daily for 5 d. At day 28, 83% had responded to alemtuzumab and 10/15 of responders were alive after a median follow up of 11 months. Infectious complications were reported in 14 patients, including CMV reactivation in 11 patients (Gómez-Almaguer *et al*, 2008). In a series of 20 patients with histologically confirmed grade III/IV steroid-refractory GvHD, the overall response rate was 70% and 1-year overall survival was 50% (Schnitzler *et al*, 2009). These results have not been replicated in all studies. In a Phase 2 trial of 10 patients, five patients responded but all died within a median of 40 d of treatment (Martínez *et al*, 2009). These studies were predominantly undertaken in patients who had not received T-cell depletion prior to transplantation and it is possible that the effect may be different in T-cell depleted patients.

Pentostatin

Pentostatin is a nucleoside analogue that is a potent inhibitor of adenosine deaminase. Cell death occurs as a result of accumulation of 2-deoxyadenosine 5-triphosphate, particularly in T-cells and Natural Killer (NK) cells. The drug also causes reduced TNF α and prolonged lymphopenia (Margolis & Vogelsang, 2000; Foss, 2006). It has been used in the treatment of both aGvHD and chronic GvHD. A Phase 1 study of 23 evaluable patients found the maximum tolerated dose to be 1.5 mg/m² per day for 3 d. Fourteen patients achieved a complete response but median survival was 85 d (Bolaños-Meade *et al*, 2005). A small retrospective series including 12 patients with aGvHD reported overall response in 6/12 patients but median survival of only 1.4 months (Pidala *et al*, 2010). Pentostatin was also used in combination with corticosteroids in one arm of a randomized Phase 2 study for initial therapy of aGvHD comparing etanercept, MMF and denileukin diftitox. The day-28 complete response rate was 38%, which was lower than MMF (60%) and denileukin diftitox (53%). Overall survival at 9 months was 47%, which was similar to denileukin diftitox and etanercept but lower than MMF (64%). The infection rate of 57% was also higher compared to MMF (44%) and etanercept (48%) (Alousi *et al*, 2009). A recent study including 23 patients with steroid-refractory aGvHD reported an 83% response rate with a 2-year survival rate of 43% (Klein *et al*, 2011).

Methotrexate

Methotrexate is commonly used in GvHD prophylaxis, but there is less evidence for its use in the management of aGvHD. Huang *et al* (2005) reported a response in 18/19 steroid-

refractory patients treated with low dose methotrexate. Wang *et al* (2011b) used low dose methotrexate combined with low dose methylprednisolone as a first line treatment in 32 patients with aGvHD and reported an overall response rate of 81%. De Lavallade *et al* (2006) reported a response in 7/12 patients with refractory aGvHD. A paediatric study reported a response rate in 7/10 paediatric patients with steroid-dependent or steroid-refractory disease (Inagaki *et al*, 2008).

Recommendation

- **The following agents are suggested as third line treatment options in acute steroid-refractory GvHD: alemtuzumab, pentostatin, mesenchymal stem cells and methotrexate (2C).**

Agents with a possible role in the management of acute GvHD

Several other agents have been used in the management of acute GvHD. These are discussed below.

Antithymocyte globulin (ATG)

MacMillan *et al* (2002b) reported some efficacy of ATG in steroid-refractory patients in a retrospective review but this has not been reported by all investigators (Roy *et al*, 1992; Arai *et al*, 2002). In a prospective study, Cragg *et al* (2000) compared equine ATG with steroids to steroids alone as initial treatment for aGvHD. Complete and partial response rates of 76% were reported in both groups. More patients experienced infectious complications in the combination arm compared to those receiving steroids alone and there was a trend towards improved survival in the prednisolone arm (Cragg *et al*, 2000). Similar results were reported by Van Lint *et al* (2006), who treated 211 patients with grade I–IV GvHD with 2 mg/kg per day of methylprednisolone for 5 d. The non-responders were then randomized to receive either a higher dose of steroids of 5 mg/kg per day for 10 d either alone or in combination with rabbit ATG. 26% of patients achieved a complete response but there was no significant difference between the two groups in terms of response rate, TRM and survival (Van Lint *et al*, 2006). The authors recognize that many centres have experience in using ATG for the treatment of acute GvHD but, in view of the lack of evidence supporting its use, suggest that the use of ATG is at the discretion of the treating physician.

Regulatory T-cells

Trzonkowski *et al* (2009) reported a transient response in one patient with aGvHD treated with human *ex vivo* expanded CD4+CD25+CD127– T regulatory cells. The use of regulatory T-cells in the management of aGvHD remains experimental at present (Trzonkowski *et al*, 2009).

Agents not currently recommended in the management of acute GvHD

Rituximab is an anti-CD20 monoclonal antibody that has been used in the treatment of chronic GvHD but its role in aGvHD is limited to case reports (Kamble *et al*, 2006). The role of visilizumab, a monoclonal antibody directed at the invariant CD3 epsilon chain of the T-cell receptor, and the anti-CD147 antibody, ABX-CBL have been used in the treatment of aGvHD but are not currently available (reviewed in Deeg, 2007).

Various other agents have been tried in the management of GvHD. These include thalidomide and azathioprine. Thalidomide was not found to be effective in the management of aGvHD (Kulkarni *et al*, 2003). There is no evidence to support the use of azathioprine in this context.

Intra-arterial methylprednisolone has been used in the management of steroid-refractory aGvHD but at present there is insufficient experience to recommend this technique (Weintraub *et al*, 2010; Milner *et al*, 2011).

Disclaimer

While the advice and information in these guidelines is believed to be true and accurate at the time of going to press, neither the authors, the British Society for Haematology, the British Society of Blood and Marrow Transplantation nor the publishers accept any legal responsibility for the content of these guidelines.

Acknowledgements

The authors are grateful to the BCSH task force and BSBMT executive committee for their support in preparing these guidelines.

Author contributions

FLD reviewed the literature and wrote the initial draft of the manuscript. MNP chaired the writing group, reviewed the literature and revised the manuscript. AC represented BCSH, reviewed the literature and revised the manuscript. GJ represented BSBMT, reviewed the literature and revised the manuscript. JS, JC, PA, PT, PM, NH and BES reviewed the literature and revised the manuscript.

Conflicts of interest

All authors have declared any potential conflicts of interest to BCSH. FLD and BES have received research funding, honoraria and speaker's fees from Therakos, a Johnson and

Johnson company. PCT has received honoraria from Therakos, a Johnson and Johnson company. MNP has participated in an advisory board for EUSA Pharma SAS. None of the other authors have declared any conflicts of interest.

Appendix 1

GRADE nomenclature for assessing levels of evidence and providing recommendations in guidelines.

Strength of recommendations

Strong (grade 1): Strong recommendations (grade 1) are made when there is confidence that the benefits do or do not outweigh harm and burden. Grade 1 recommendations can be applied uniformly to most patients. Regard as 'recommend'.

Weak (grade 2): Where the magnitude of benefit or not is less certain a weaker grade 2 recommendation is made. Grade 2 recommendations require judicious application to individual patients. Regard as 'suggest'.

Quality of evidence

The quality of evidence is graded as high (A), moderate (B) or low (C). To put this in context it is useful to consider the uncertainty of knowledge and whether further research could change what we know or our certainty.

(A) High: Further research is very unlikely to change confidence in the estimate of effect. Current evidence derived from randomized clinical trials without important limitations.

(B) Moderate: Further research may well have an important impact on confidence in the estimate of effect and may change the estimate. Current evidence derived from randomized clinical trials with important limitations (e.g. inconsistent results, imprecision – wide confidence intervals or methodological flaws – e.g. lack of blinding, large losses to follow up, failure to adhere to intention to treat analysis), or very strong evidence from observational studies or case series (e.g. large or very large and consistent estimates of the magnitude of a treatment effect or demonstration of a dose-response gradient).

(C) Low: Further research is likely to have an important impact on confidence in the estimate of effect and is likely to change the estimate. Current evidence from observational studies, case series or just opinion.

References

Akpek, G., Boitnott, J.K., Lee, L.A., Hallick, J.P., Torbenson, M., Jacobsohn, D.A., Arai, S.,

Anders, V. & Vogelsang, G.B. (2002) Hepatic variant of graft-versus-host disease after donor lymphocyte infusion. *Blood*, **100**, 3903–3907.

Allison, A.C. & Eugui, E.M. (2000) Mycophenolate mofetil and its mechanisms of action. *Immunopharmacology*, **47**, 85–118.

- Alousi, A.M., Weisdorf, D.J., Logan, B.R., Bolaños-Meade, J., Carter, S., Difronzo, N., Pasquini, M., Goldstein, S.C., Ho, V.T., Hayes-Lattin, B., Wingard, J.R., Horowitz, M.M. & Levine, J.E. Blood and Marrow Transplant Clinical Trials Network (2009) Etanercept, mycophenolate, denileukin, or pentostatin plus corticosteroids for acute graft-versus-host disease: a randomized phase 2 trial from the Blood and Marrow Transplant Clinical Trials Network. *Blood*, **114**, 511–517.
- Anasetti, C., Hansen, J.A., Waldmann, T.A., Appelbaum, F.R., Davis, J., Deeg, H.J., Doney, K., Martin, P.J., Nash, R., Storb, R., Sullivan, K., Witherspoon, R.P., Binger, M., Chizzonite, R., Hakimi, J., Mould, D., Satoh, H. & Light, S.E. (1994) Treatment of acute graft-versus-host disease with humanized anti-Tac: an antibody that binds to the interleukin-2 receptor. *Blood*, **84**, 1320–1327.
- Arai, S., Margolis, J., Zahurak, M., Anders, V. & Vogelsang, G.B. (2002) Poor outcome in steroid-refractory graft-versus-host disease with antithymocyte globulin treatment. *Biology of Blood and Marrow Transplantation*, **8**, 155–160.
- Basara, N., Kiehl, M.G., Blau, W., Römer, E., Bischhoff, M., Schmetzer, B., Kirsten, D., Günzelmann, S. & Fauser, A.A. (2001) Mycophenolate Mofetil in the treatment of acute and chronic GVHD in hematopoietic stem cell transplant patients: four years of experience. *Transplant Proceedings*, **33**, 2121–2123.
- Bay, J.O., Dhédin, N., Goerner, M., Vannier, J.P., Marie-Cardine, A., Stamatoullas, A., Jouet, J.P., Yakoub-Agha, I., Tabrizi, R., Faucher, C., Diez-Martin, J.L., Nunez, G., Parody, R., Milpied, N., Espérou, H., Garban, F., Galambrun, C., Kwiatkowski, F., Darlavoix, I., Zinaï, A., Fischer, A., Michallet, M. & Vernant, J.P. (2005) Inolimomab in steroid-refractory acute graft-versus-host disease following allogeneic hematopoietic stem cell transplantation: retrospective analysis and comparison with other interleukin-2 receptor antibodies. *Transplantation*, **80**, 782–788.
- Benito, A.I., Furlong, T., Martin, P.J., Anasetti, C., Appelbaum, F.R., Doney, K., Nash, R.A., Papanannopoulou, T., Storb, R., Sullivan, K.M., Witherspoon, R. & Deeg, H.J. (2001) Sirolimus (rapamycin) for the treatment of steroid-refractory acute graft-versus-host disease. *Transplantation*, **72**, 1924–1929.
- Bertz, H., Afting, M., Kreisel, W., Duffner, U., Greinwald, R. & Finke, J. (1999) Feasibility and response to budesonide as topical corticosteroid therapy for acute intestinal GVHD. *Bone Marrow Transplantation*, **24**, 1185–1189.
- Bladon, J. & Taylor, P.C. (2006) Extracorporeal photopheresis: a focus on apoptosis and cytokines. *Journal of Dermatological Science*, **43**, 85–94.
- Bolaños-Meade, J., Jacobsohn, D.A., Margolis, J., Ogden, A., Wientjes, M.G., Byrd, J.C., Lucas, D.M., Anders, V., Phelps, M., Grever, M.R. & Vogelsang, G.B. (2005) Pentostatin in steroid-refractory acute graft-versus-host disease. *Journal of Clinical Oncology*, **23**, 2661–2668.
- Bordignon, P., Dimicoli, S., Clement, L., Baumann, C., Salmon, A., Witz, F. & Feugier, P. (2006) Daclizumab, an efficient treatment for steroid-refractory acute graft-versus-host disease. *British Journal of Haematology*, **135**, 382–385.
- Busca, A., Locatelli, F., Marmont, F., Ceretto, C. & Falda, M. (2007) Recombinant human soluble tumor necrosis factor receptor fusion protein as treatment for steroid refractory graft-versus-host disease following allogeneic hematopoietic stem cell transplantation. *American Journal of Hematology*, **82**, 45–52.
- Byun, H.J., Yang, J.I., Kim, B.K. & Cho, K.H. (2011) Clinical differentiation of acute cutaneous graft-versus-host disease from drug hypersensitivity reactions. *Journal of the American Academy of Dermatology*, **65**, 726–732.
- Cahn, J.Y., Klein, J.P., Lee, S.J., Milpied, N., Blaise, D., Antin, J.H., Leblond, V., Ifrah, N., Jouet, J.P., Loberiza, F., Ringden, O., Barrett, A.J., Horowitz, M.M. & Socié, G. (2005) Prospective evaluation of 2 acute graft-versus-host (GVHD) grading systems: a joint Société Française de Greffe de Moëlle et Thérapie Cellulaire (SFGM-TC), Dana Farber Cancer Institute (DFCI), and International Bone Marrow Transplant Registry (IBMTR) prospective study. *Blood*, **106**, 1495–1500.
- Carella, A.M., Beltrami, G., Scalzulli, P.R., Carella, Jr, A.M. & Corsetti, M.T. (2004) Alemtuzumab can successfully treat steroid-refractory acute graft-versus-host disease (aGVHD). *Bone Marrow Transplantation*, **33**, 131–132.
- Couriel, D., Saliba, R., Hicks, K., Ippoliti, C., de Lima, M., Hosing, C., Khouri, I., Andersson, B., Gajewski, J., Donato, M., Anderlini, P., Kontoyiannis, D.P., Cohen, A., Martin, T., Giral, S. & Champlin, R. (2004) Tumor necrosis factor- α blockade for the treatment of aGVHD. *Blood*, **104**, 649–654.
- Couriel, D.R., Saliba, R., de Lima, M., Giral, S., Andersson, B., Khouri, I., Hosing, C., Ippoliti, C., Shpall, E.J., Champlin, R. & Alousi, A. (2009) A phase III study of infliximab and corticosteroids for the initial treatment of acute graft-versus-host disease. *Biology of Blood and Marrow Transplantation*, **15**, 1555–1562.
- Cragg, L., Blazar, B.R., Defor, T., Kolatker, N., Miller, W., Kersey, J., Ramsay, M., McGlave, P., Filipovich, A. & Weisdorf, D. (2000) A randomized trial comparing prednisone with antithymocyte globulin/prednisone as an initial systemic therapy for moderately severe acute graft-versus-host disease. *Biology of Blood and Marrow Transplantation*, **6**, 441–447.
- Cruz-Correa, M., Poonawala, A., Abraham, S.C., Wu, T.T., Zahurak, M., Vogelsang, G., Kallou, A.N. & Lee, L.A. (2002) Endoscopic findings predict the histologic diagnosis in gastrointestinal graft-versus-host disease. *Endoscopy*, **34**, 808–813.
- Dall'Amico, R. & Messina, C. (2002) Extracorporeal photochemotherapy for the treatment of graft-versus-host disease. *Therapeutic Apheresis*, **6**, 296–304.
- Das-Gupta, E., Watson, J., Byrne, J. & Russell, N. (2011) A single centre experience of the efficacy of extracorporeal photopheresis in the treatment of steroid-refractory acute graft-versus-host disease. *Bone Marrow Transplantation*, **46**, S114.
- Deeg, H.J. (2007) How I treat refractory aGVHD. *Blood*, **109**, 4119–4126.
- Devergie, A. (2008) Graft versus host disease, chapter 11. In: ESH-EBMT Handbook, (eds J. Apperley, E. Carreras, E. Gluckman, A. Gratwohl & T. Masszi), pp. 218–236. Forum Service Editore, Genoa, Italy.
- Dignan, F.L., Amrolia, P., Clark, A., Cornish, J., Jackson, G., Mahendra, P., Scarisbrick, J.J., Taylor, P.C., Shaw, B.E. & Potter, M.N. on behalf of the Haemato-oncology Task Force of the British Committee for Standards in Haematology and the British Society for Blood and Marrow Transplantation (2012a) Diagnosis and management of chronic graft-versus-host disease. *British Journal of Haematology*, **158**, 46–61.
- Dignan, F.L., Scarisbrick, J.J., Cornish, J., Clark, A., Amrolia, P., Jackson, G., Mahendra, P., Taylor, P.C., Shah, P., Lightman, S., Fortune, F., Kibbler, C., Andreyev, J., Albanese, A., Hadzic, N., Potter, M.N. & Shaw, B.E. on behalf of the Haemato-oncology Task Force of the British Committee for Standards in Haematology and the British Society for Blood and Marrow Transplantation (2012b) BCSH guideline: Organ-specific management and supportive care in graft-versus-host disease. *British Journal of Haematology*, **158**, 62–78.
- Duarte, R.F., Delgado, J., Shaw, B.E., Wrench, D.J., Ethell, M., Patch, D., Dhillion, A.P., Mackinnon, S., Potter, M.N. & Quaglia, A.F. (2005) Histologic features of the liver biopsy predict the clinical outcome for patients with graft-versus-host disease of the liver. *Biology of Blood and Marrow Transplantation*, **11**, 805–813.
- Ferrara, J.L. & Deeg, H.J. (1991) Graft-versus-host disease. *New England Journal of Medicine*, **324**, 667–674.
- Ferrara, J.L., Levine, J.E., Reddy, P. & Holler, E. (2009) Graft-versus-host disease. *Lancet*, **373**, 1550–1561.
- Filipovich, A.H., Weisdorf, D., Pavletic, S., Socie, G., Wingard, J.R., Lee, S.J., Martin, P., Chien, J., Przepiora, D., Couriel, D., Cowen, E.W., Dinndorf, P., Farrell, A., Hartzman, R., Henslee-Downey, J., Jacobsohn, D., McDonald, G., Mittleman, B., Rizzo, J.D., Robinson, M., Schubert, M., Schultz, K., Shulman, H., Turner, M., Vogelsang, G. & Flowers, M.E. (2005) National Institutes of Health consensus development project on criteria for clinical trials in chronic graft-versus-host disease: I. Diagnosis and staging working group report. *Biology of Blood and Marrow Transplantation*, **11**, 945–956.
- Firoz, B.F., Lee, S.J., Nghiem, P. & Qureshi, A.A. (2006) Role of skin biopsy to confirm sus-

- pected acute graft-vs-host disease: results of decision analysis. *Archives of Dermatology*, **142**, 175–182.
- Foss, F.M. (2006) The role of purine analogues in low-intensity regimens with allogeneic hematopoietic stem cell transplantation. *Seminars in Hematology*, **43**, S35–S43.
- Fujii, N., Takenaka, K., Shinagawa, K., Ikeda, K., Maeda, Y., Sunami, K., Hiramatsu, Y., Matsuo, K., Ishimaru, F., Niiya, K., Yoshino, T., Hirabayashi, N. & Harada, M. (2001) Hepatic graft-versus-host disease presenting as an acute hepatitis after allogeneic peripheral blood stem cell transplantation. *Bone Marrow Transplantation*, **27**, 1007–1010.
- Funke, V.A., de Medeiros, C.R., Setúbal, D.C., Ruiz, J., Bitencourt, M.A., Bonfim, C.M., Neto, J.Z. & Pasquini, R. (2006) Therapy for severe refractory acute graft-versus-host disease with basiliximab, a selective interleukin-2 receptor antagonist. *Bone Marrow Transplantation*, **37**, 961–965.
- Furlong, T., Storb, R., Anasetti, C., Appelbaum, F. R., Deeg, H.J., Doney, K., Martin, P., Sullivan, K., Witherspoon, R. & Nash, R.A. (2000) Clinical outcome after conversion to FK 506 (tacrolimus) therapy for acute graft-versus-host disease resistant to cyclosporine or for cyclosporine-associated toxicities. *Bone Marrow Transplantation*, **26**, 985–991.
- Furlong, T., Martin, P., Flowers, M.E., Carnevale-Schianca, F., Yatscoff, R., Chauncey, T., Appelbaum, F.R., Deeg, H.J., Doney, K., Witherspoon, R., Storer, B., Sullivan, K.M., Storb, R. & Nash, R.A. (2009) Therapy with mycophenolate mofetil for refractory acute and chronic GVHD. *Bone Marrow Transplantation*, **44**, 739–748.
- Ghez, D., Rubio, M.T., Maillard, N., Suarez, F., Chandresis, M.O., Delarue, R., Deau-Fischer, B., Varet, B., Hermine, O. & Buzyn, A. (2009) Rapamycin for refractory acute graft-versus-host disease. *Transplantation*, **88**, 1081–1087.
- Glucksberg, H., Storb, R., Fefer, A., Buckner, C.D., Neiman, P.E., Clift, R.A., Lerner, K.G. & Thomas, E.D. (1974) Clinical manifestations of graft-versus-host disease in human recipients of marrow from HL-A-matched sibling donors. *Transplantation*, **18**, 295–304.
- Goker, H., Haznedaroglu, I.C. & Chao, N.J. (2001) Acute graft-vs-host disease: pathobiology and management. *Experimental Hematology*, **29**, 259–277.
- Gómez-Almaguer, D., Ruiz-Argüelles, G.J., del Carmen Tarín-Arzaga, L., González-Llano, O., Gutiérrez-Aguirre, H., Cantú-Rodríguez, O., Jaime-Pérez, J., Carrasco-Yalán, A. & Giral, S. (2008) Alemtuzumab for the treatment of steroid-refractory acute graft-versus-host disease. *Biology of Blood and Marrow Transplantation*, **14**, 10–15.
- Gratwohl, A., Hermans, J., Apperley, J., Arcese, W., Bacigalupo, A., Bandini, G., di Bartolomeo, P., Boogaerts, M., Bosi, A., Carreras, E., Devergie, A., Ferrant, A., Fibbe, W.E., Frassoni, F., Gahrton, G., Goldman, J., Iriondo, A., Jacobsen, J., Kolb, H.J., Link, H., Michallet, M., Prentice, H.G., Reiffers, J., Rhee, F.V., Ruutu, T., Schwaighofer, H., Vernant, J.P., de Witte, T. & Niederwieser, D. (1995) Acute graft-versus-host disease: grade and outcome in patients with chronic myelogenous leukemia. Working Party Chronic Leukemia of the European Group for Blood and Marrow Transplantation. *Blood*, **86**, 813–818.
- Greinix, H.T., Volc-Platzer, B., Rabitsch, W., Gmeinhardt, B., Guevara-Pineda, C., Kalhs, P., Krutmann, J., Hönigsmann, H., Ciovia, M. & Knobler, R.M. (1998) Successful use of extracorporeal photochemotherapy in the treatment of severe acute and chronic graft-versus-host disease. *Blood*, **92**, 3098–3104.
- Greinix, H.T., Knobler, R.M., Worel, N., Schneider, B., Schneeberger, A., Hoecker, P., Mitterbauer, M., Rabitsch, W., Schulenburg, A. & Kalhs, P. (2006) The effect of intensified extracorporeal photochemotherapy on long-term survival in patients with severe acute graft-versus-host disease. *Haematologica*, **91**, 405–408.
- Hale, G. (2001) The CD52 antigen and development of the CAMPATH antibodies. *Cytotherapy*, **3**, 137–143.
- Hattori, K., Hirano, T., Miyajima, H., Yamakawa, N., Tateno, M., Oshimi, K., Kayagaki, N., Yagita, H. & Okumura, K. (1998) Differential effects of anti-Fas ligand and anti-tumor necrosis factor alpha antibodies on acute graft-versus-host disease pathologies. *Blood*, **91**, 4051–4055.
- Hervé, P., Flesch, M., Tiberghien, P., Wijdenes, J., Racadot, E., Bordigoni, P., Plouvier, E., Stephan, J.L., Bourdeau, H. & Holler, E. (1992) Phase I-II trial of a monoclonal anti-tumor necrosis factor alpha antibody for the treatment of refractory severe acute graft-versus-host disease. *Blood*, **79**, 3362–3368.
- Hettiaratchy, S. & Papini, R. (2004) Initial management of a major burn: II—assessment and resuscitation. *British Medical Journal*, **329**, 101–103.
- Hings, I.M., Filipovich, A.H., Miller, W.J., Blazar, B.L., McGlave, P.B., Ramsay, N.K., Kersey, J.H. & Weisdorf, D.J. (1993) Prednisone therapy for acute graft-versus-host disease: short- versus long-term treatment. A prospective randomized trial. *Transplantation*, **56**, 577–580.
- Ho, V.T., Zahrieh, D., Hochberg, E., Micale, E., Levin, J., Reynolds, C., Steckel, S., Cutler, C., Fisher, D.C., Lee, S.J., Alyea, E.P., Ritz, J., Soiffer, R.J. & Antin, J.H. (2004) Safety and efficacy of denileukin difitox in patients with steroid-refractory acute graft-versus-host disease after allogeneic hematopoietic stem cell transplantation. *Blood*, **104**, 1224–1226.
- Hockenbery, D.M., Cruickshank, S., Rodell, T.C., Gooley, T., Schuening, F., Rowley, S., David, D., Brunvand, M., Berryman, B., Abhyankar, S., Bouvier, M. & McDonald, G.B. (2007) A randomized, placebo-controlled trial of oral beclomethasone dipropionate as a prednisone-sparing therapy for gastrointestinal graft-versus-host disease. *Blood*, **109**, 4557–4563.
- Hoda, D., Pidala, J., Salgado-Vila, N., Kim, J., Perkins, J., Bookout, R., Field, T., Perez, L., Ayala, E., Ochoa-Bayona, J.L., Raychaudhuri, J., Alsina, M., Greene, J., Janssen, W., Fernandez, H.F., Anasetti, C. & Kharfan-Dabaja, M.A. (2010) Sirolimus for treatment of steroid-refractory acute graft-versus-host disease. *Bone Marrow Transplantation*, **45**, 1347–1351.
- Hsu, B., May, R., Carrum, G., Krance, R. & Przepiorka, D. (2001) Use of antithymocyte globulin for treatment of steroid-refractory acute graft-versus-host disease: an international practice survey. *Bone Marrow Transplantation*, **28**, 945–950.
- Huang, X.J., Jiang, Q., Chen, H., Xu, L., Liu, D., Chen, Y., Han, W., Zhang, Y., Liu, K. & Lu, D. (2005) Low-dose methotrexate for the treatment of graft-versus-host disease after allogeneic hematopoietic stem cell transplantation. *Bone Marrow Transplantation*, **36**, 343–348.
- Ibrahim, R.B., Abidi, M.H., Cronin, S.M., Lum, L. G., Al-Kadhimi, Z., Ratanatharathorn, V. & Uberti, J.P. (2009) Nonabsorbable corticosteroids use in the treatment of gastrointestinal graft-versus-host disease. *Biology of Blood and Marrow Transplantation*, **15**, 395–405.
- Inagaki, J., Nagatoshi, Y., Hatano, M., Isomura, N., Sakiyama, M. & Okamura, J. (2008) Low-dose MTX for the treatment of acute and chronic graft-versus-host disease in children. *Bone Marrow Transplantation*, **41**, 571–577.
- Iyer, R.V., Hahn, T., Roy, H.N., Battiwalla, M., Cooper, M., Anderson, B., Paplham, P., Brown, K., Bambach, B., Segal, B.H. & McCarthy, Jr, P. L. (2005) Long-term use of oral beclomethasone dipropionate for the treatment of gastrointestinal graft-versus-host disease. *Biology of Blood and Marrow Transplantation*, **11**, 587–592.
- Kamble, R., Oholendt, M. & Carrum, G. (2006) Rituximab responsive refractory acute graft-versus-host disease. *Biology of Blood and Marrow Transplantation*, **12**, 1201–1202.
- Karlsson, H., Samarasinghe, S., Ball, L.M., Sundberg, B., Lankester, A.C., Dazzi, F., Uzunel, M., Rao, K., Veys, P., Le Blanc, K., Ringdén, O. & Amrolia, P.J. (2008) Mesenchymal stem cells exert differential effects on alloantigen and virus-specific T-cell responses. *Blood*, **112**, 532–541.
- Kebricai, P., Isola, L., Bahceci, E., Holland, K., Rowley, S., McGuirk, J., Devetten, M., Jansen, J., Herzig, R., Schuster, M., Monroy, R. & Uberti, J. (2009) Adult human mesenchymal stem cells added to corticosteroid therapy for the treatment of acute graft-versus-host disease. *Biology of Blood and Marrow Transplantation*, **15**, 804–811.
- Klein, S.A., Bug, G., Mousset, S., Hofmann, W.K., Hoelzer, D. & Martin, H. (2011) Long term outcome of patients with steroid-refractory acute intestinal graft versus host disease after treat-

- ment with pentostatin. *British Journal of Haematology*, **154**, 143–146.
- Kobbe, G., Schneider, P., Rohr, U., Fenk, R., Neumann, F., Aivado, M., Dietze, L., Kronenwett, R., Hünerlitürkoglu, A. & Haas, R. (2001) Treatment of severe steroid refractory acute graft-versus-host disease with infliximab, a chimeric human/mouse antiTNF α antibody. *Bone Marrow Transplantation*, **28**, 47–49.
- Krejci, M., Doubek, M., Buchler, T., Brychtova, Y., Vorlicek, J. & Mayer, J. (2005) Mycophenolate mofetil for the treatment of acute and chronic steroid-refractory graft-versus-host disease. *Annals of Haematology*, **84**, 681–685.
- Kulkarni, S., Powles, R., Sirohi, B., Treleaven, J., Saso, R., Horton, C., Atra, A., Ortin, M., Rudin, C., Goyal, S., Sankpal, S., Meller, S., Pinkerton, C.R., Mehta, J. & Singhal, S. (2003) Thalidomide after allogeneic haematopoietic stem cell transplantation: activity in chronic but not in acute graft-versus-host disease. *Bone Marrow Transplantation*, **32**, 165–170.
- de Lavallade, H., Mohty, M., Faucher, C., Fürst, S., El-Cheikh, J. & Blaise, D. (2006) Low-dose methotrexate as salvage therapy for refractory graft-versus-host disease after reduced-intensity conditioning allogeneic stem cell transplantation. *Haematologica*, **91**, 1438–1440.
- Le Blanc, K., Rasmusson, I., Sundberg, B., Götherström, C., Hassan, M., Uzunel, M. & Ringdén, O. (2004) Treatment of severe acute graft-versus-host disease with third party haplo-identical mesenchymal stem cells. *Lancet*, **363**, 1439–1441.
- Le Blanc, K., Frassoni, F., Ball, L., Locatelli, F., Roelofs, H., Lewis, I., Lanino, E., Sundberg, B., Bernardo, M.E., Remberger, M., Dini, G., Egeler, R.M., Bacigalupo, A., Fibbe, W. & Ringdén, O. (2008) Mesenchymal stem cells for treatment of steroid-resistant, severe, acute graft-versus-host disease: a phase II study. Developmental Committee of the European Group for Blood and Marrow Transplantation. *Lancet*, **371**, 1579–1586.
- Lee, S.J., Zahrieh, D., Agura, E., MacMillan, M.L., Maziarz, R.T., McCarthy, Jr, P.L., Ho, V.T., Cutler, C., Alyea, E.P., Antin, J.H. & Soiffer, R.J. (2004) Effect of up-front daclizumab when combined with steroids for the treatment of acute graft-versus-host disease: results of a randomized trial. *Blood*, **104**, 1559–1564.
- Levine, J.E., Paczesny, S., Mineishi, S., Braun, T., Choi, S.W., Hutchinson, R.J., Jones, D., Khaled, Y., Kitko, C.L., Bickley, D., Krijanovski, O., Reddy, P., Yanik, G. & Ferrara, J.L. (2008) Etanercept plus methylprednisolone as initial therapy for acute graft-versus-host disease. *Blood*, **111**, 2470–5.
- Liu, J., Wang, H.X., Duan, L.N., Yang, H.M., Xue, M., Zhu, L., Ding, L. & Wang, Z.D. (2009) [Efficacy of anti-CD25 monoclonal antibody used in treating steroid-resistant acute graft-versus-host disease following haploidentical bone marrow transplantation.]. *Zhongguo Shi Yan Xue Ye Xue Za Zhi*, **17**, 160–163.
- MacMillan, M.L., Weisdorf, D.J., Wagner, J.E., DeFor, T.E., Burns, L.J., Ramsay, N.K., Davies, S.M. & Blazar, B.R. (2002a) Response of 443 patients to steroids as primary therapy for acute graft-versus-host disease: comparison of grading systems. *Biol Blood Marrow Transplant*, **8**, 387–394.
- MacMillan, M.L., Weisdorf, D.J., Davies, S.M., DeFor, T.E., Burns, L.J., Ramsay, N.K., Wagner, J.E. & Blazar, B.R. (2002b) Early antithymocyte globulin therapy improves survival in patients with steroid-resistant acute graft-versus-host disease. *Biology of Blood and Marrow Transplantation*, **8**, 40–46.
- Majumdar, M.K., Thiede, M.A., Haynesworth, S.E., Bruder, S.P. & Gerson, S.L. (2000) Human marrow-derived mesenchymal stem cells (MSCs) express hematopoietic cytokines and support long-term hematopoiesis when differentiated toward stromal and osteogenic lineages. *Journal of Hematotherapy and Stem Cell Research*, **9**, 841–848.
- Margolis, J. & Vogelsang, G. (2000) An old drug for a new disease: pentostatin (Nipent) in acute graft-versus-host disease. *Seminars in Oncology*, **27**, 72–77.
- Marshall, S.R. (2006) Technology insight: ECP for the treatment of GvHD—can we offer selective immune control without generalized immunosuppression? *Nature Clinical Practice Oncology*, **3**, 302–314.
- Martin, P.J., Schoch, G., Fisher, L., Byers, V., Anasetti, C., Appelbaum, F.R., Beatty, P.G., Doney, K., McDonald, G.B. & Sanders, J.E. (1990) A retrospective analysis of therapy for acute graft-versus-host disease: initial treatment. *Blood*, **76**, 1464–1472.
- Martin, P.J., Uberti, J.P., Soiffer, R.J., Klingemann, H., Waller, E.K., Daly, A.S., Herrmann, R.P. & Kebriaei, P. (2010) Prochymal improves response rates in patients with steroid-refractory acute graft versus host disease (SR-GVHD) involving the liver and gut: results of a randomized, placebo-controlled, multicenter phase III trial in GVHD. *Biology of Blood and Marrow Transplantation*, **16**, S169–S170.
- Martínez, C., Solano, C., Ferrá, C., Sampol, A., Valcárcel, D. & Pérez-Simón, J.A. Spanish Group for Stem Cell Transplantation (Grupo Español de Trasplante Hemopoyético y Terapia Celular) (2009) Alemtuzumab as treatment of steroid-refractory acute graft-versus-host disease: results of a phase II study. *Biology of Blood and Marrow Transplantation*, **15**, 639–642.
- Marty, F.M., Lee, S.J., Fahey, M.M., Alyea, E.P., Soiffer, R.J., Antin, J.H. & Baden, L.R. (2003) Infliximab use in patients with severe graft-versus-host disease and other emerging risk factors of non-Candida invasive fungal infections in allogeneic hematopoietic stem cell transplant recipients: a cohort study. *Blood*, **102**, 2768–2776.
- Massenkeil, G., Rackwitz, S., Genvresse, I., Rosen, O., Dörken, B. & Arnold, R. (2002) Basiliximab is well tolerated and effective in the treatment of steroid-refractory acute graft-versus-host disease after allogeneic stem cell transplantation. *Bone Marrow Transplantation*, **30**, 899–903.
- McDonald, G.B., Bouvier, M., Hockenbery, D.M., Stern, J.M., Gooley, T., Farrand, A., Murakami, C. & Levine, D.S. (1998) Oral beclomethasone dipropionate for treatment of intestinal graft-versus-host disease: a randomized, controlled trial. *Gastroenterology*, **115**, 28–35.
- Mielcarek, M., Storer, B.E., Boeckh, M., Carpenter, P.A., McDonald, G.B., Deeg, H.J., Nash, R.A., Flowers, M.E., Doney, K., Lee, S., Marr, K.A., Furlong, T., Storb, R., Appelbaum, F.R. & Martin, P.J. (2009) Initial therapy of acute graft-versus-host disease with low-dose prednisone does not compromise patient outcomes. *Blood*, **113**, 2888–2894.
- Milner, L.A., Becker, M.W., Bernstein, S.H., Bruckner, L., Friedberg, J.W., Holland, G.A., Ifthikharuddin, J.J., Liesveld, J.L., Mathes, E.J., Menchel, H.L., Mullen, C.A., Sasson, T. & Phillips, G.L. 2nd (2011) Intra-arterial methylprednisolone for the management of steroid-refractory acute gastrointestinal and hepatic graft versus host disease. *American Journal of Hematology*, **86**, 712–714.
- Nevo, S., Enger, C., Swan, V., Wojno, K.J., Fuller, A.K., Altomonte, V., Braine, H.G., Noga, S.J. & Vogelsang, G.B. (1999) Acute bleeding after allogeneic bone marrow transplantation: association with GvHD and effect on survival. *Transplantation*, **67**, 681–689.
- Onishi, C., Ohashi, K., Sawada, T., Nakano, M., Kobayashi, T., Yamashita, T., Akiyama, H. & Sakamaki, H. (2010) A high risk of life-threatening infectious complications in mycophenolate mofetil treatment for acute or chronic graft-versus-host disease. *International Journal of Hematology*, **91**, 464–470.
- Oshrine, B., Lehmann, L.E. & Duncan, C.N. (2011) Safety and utility of liver biopsy after pediatric hematopoietic stem cell transplantation. *Journal of Pediatric Hematology/Oncology*, **33**, 92–97.
- Paczesny, S., Braun, T.M., Levine, J.E., Hogan, J., Crawford, J., Coffing, B., Olsen, S., Choi, S.W., Wang, H., Faca, V., Pitteri, S., Zhang, Q., Chin, A., Kitko, C., Mineishi, S., Yanik, G., Peres, E., Hanauer, D., Wang, Y., Reddy, P., Hanash, S. & Ferrara, J.L. (2010) Elafin is a biomarker of graft-versus-host disease of the skin. *Science Translational Medicine*, **2**, 13ra2.
- Patriarca, F., Sperotto, A., Damiani, D., Morreale, G., Bonifazi, F., Olivieri, A., Ciceri, F., Milone, G., Cesaro, S., Bandini, G., Dini, G., Corradini, P. & Fanin, R. (2004) Infliximab treatment for steroid-refractory acute graft-versus-host disease. *Haematologica*, **89**, 1352–1359.
- Pérez-Simón, J.A., López-Villar, O., Andreu, E.J., Rifón, J., Muntion, S., Campelo, M.D., Sánchez-Guijo, F.M., Martínez, C., Valcarcel, D. & Cañizo, C.D. (2011) Mesenchymal stem cells expanded in vitro with human serum for the treatment of acute and chronic graft-versus-host disease: results of a phase I/II clinical trial. *Haematologica*, **96**, 1072–1076.

- Perfetti, P., Carlier, P., Strada, P., Gualandi, F., Ochini, D., Van Lint, M.T., Ibatíci, A., Lamparelli, T., Bruno, B., Raiola, A.M., Dominietto, A., Di Grazia, C., Bregante, S., Zia, S., Ferrari, G. M., Stura, P., Pogliani, E. & Bacigalupo, A. (2008) Extracorporeal photopheresis for the treatment of steroid refractory aGvHD. *Bone Marrow Transplantation*, **42**, 609–617.
- Perotti, C., Torretta, L., Viarengo, G., Roveda, L., Bernuzzi, S., Carbone, S., Del Fante, C., La Torre, R., Locatelli, F., Bonetti, F., Gabba, P., Bellosta, M. & Salvaneschi, L. (1999) Feasibility and safety of a new technique of extracorporeal photochemotherapy: experience of 240 procedures. *Haematologica*, **84**, 237–241.
- Perotti, C., Del Fante, C., Tinelli, C., Viarengo, G., Scudeller, L., Zecca, M., Locatelli, F. & Salvaneschi, L. (2010) Extracorporeal photochemotherapy in graft-versus-host disease: a longitudinal study on factors influencing the response and survival in pediatric patients. *Transfusion*, **50**, 1359–1369.
- Perritt, D. (2006) Potential mechanisms of photopheresis in hematopoietic stem cell transplantation. *Biology of Blood and Marrow Transplantation*, **12**, 7–12.
- Pidala, J., Kim, J., Field, T., McBride, A., Kharfan-Dabaja, M., Perkins, J., Fernandez, H., Perez, L., Ayala, E. & Anasetti, C. (2009) Infliximab for managing steroid-refractory acute graft-versus-host disease. *Biology of Blood and Marrow Transplantation*, **15**, 1116–1121.
- Pidala, J., Kim, J., Roman-Diaz, J., Shapiro, J., Nishihori, T., Bookout, R., Anasetti, C. & Kharfan-Dabaja, M.A. (2010) Pentostatin as rescue therapy for glucocorticoid-refractory acute and chronic graft-versus-host disease. *Annals of Transplantation*, **15**, 21–29.
- Pidala, J., Tomblyn, M., Nishihori, T., Field, T., Ayala, E., Perkins, J., Fernandez, H., Locke, F., Perez, L., Ochoa, L., Alsina, M. & Anasetti, C. (2011) Sirolimus demonstrates activity in the primary therapy of acute graft-versus-host disease without systemic glucocorticoids. *Haematologica*, **96**, 1351–1356.
- Piñana, J.L., Valcárcel, D., Martino, R., Moreno, M.E., Sureda, A., Briones, J., Brunet, S. & Sierra, J. (2006) Encouraging results with inolimomab (anti-IL-2 receptor) as treatment for refractory acute graft-versus-host disease. *Biology of Blood and Marrow Transplantation*, **12**, 1135–1141.
- Pittenger, M.F., Mackay, A.M., Beck, S.C., Jaiswal, R.K., Douglas, R., Mosca, J.D., Moorman, M.A., Simonetti, D.W., Craig, S. & Marshak, D.R. (1999) Multilineage potential of adult human mesenchymal stem cells. *Science*, **284**, 143–147.
- Ponec, R.J., Hackman, R.C. & McDonald, G.B. (1999) Endoscopic and histologic diagnosis of intestinal graft-versus-host disease after marrow transplantation. *Gastrointestinal Endoscopy*, **49**, 612–621.
- Prasad, V.K., Lucas, K.G., Kleiner, G.I., Talano, J. A., Jacobsohn, D., Broadwater, G., Monroy, R. & Kurtzberg, J. (2011) Efficacy and safety of ex vivo cultured adult human mesenchymal stem cells (Prochymal™) in pediatric patients with severe refractory acute graft-versus-host disease in a compassionate use study. *Biology of Blood and Marrow Transplantation*, **17**, 534–541.
- Przepiorka, D., Weisdorf, D., Martin, P., Klingemann, H.G., Beatty, P., Hows, J. & Thomas, E. D. (1995) 1994 consensus conference on AG-vHD grading. *Bone Marrow Transplantation*, **15**, 825–828.
- Przepiorka, D., Kernan, N.A., Ippoliti, C., Papadopoulos, E.B., Giral, S., Khouri, I., Lu, J.G., Gajewski, J., Durett, A., Cleary, K., Champlin, R., Andersson, B.S. & Light, S. (2000) Daclizumab, a humanized anti-interleukin-2 receptor alpha chain antibody, for treatment of acute graft-versus-host disease. *Blood*, **95**, 83–89.
- Rager, A., Frey, N., Goldstein, S.C., Reshef, R., Hexner, E.O., Loren, A., Luger, S.M., Perl, A., Tsai, D., Davis, J., Vozniak, M., Smith, J., Stadtmayer, E.A. & Porter, D.L. (2011) Inflammatory cytokine inhibition with combination daclizumab and infliximab for steroid-refractory aGvHD. *Bone Marrow Transplantation*, **46**, 430–435.
- Rao, K., Rao, A., Karlsson, H., Jagani, M., Veys, P. & Amrolia, P.J. (2009) Improved survival and preserved antiviral responses after combination therapy with daclizumab and infliximab in steroid-refractory graft-versus-host disease. *Journal of Pediatric Hematology/Oncology*, **31**, 456–461.
- Reddy, P. & Ferrara, J.L. (2003) Immunobiology of acute graft-versus-host disease. *Blood Reviews*, **17**, 187–194.
- Ross, W.A., Ghosh, S., Dekovich, A.A., Liu, S., Ayers, G.D., Cleary, K.R., Lee, J.H. & Couriel, D. (2008) Endoscopic biopsy diagnosis of acute gastrointestinal graft-versus-host disease: rectosigmoid biopsies are more sensitive than upper gastrointestinal biopsies. *American Journal of Gastroenterology*, **103**, 982–989.
- Rowlings, P.A., Przepiorka, D., Klein, J.P., Gale, R.P., Passweg, J.R., Henslee-Downey, P.J., Cahn, J.Y., Calderwood, S., Gratwohl, A., Socić, G., Abecasis, M.M., Sobocinski, K.A., Zhang, M.J. & Horowitz, M.M. (1997) IBMTR Severity Index for grading acute graft-versus-host disease: retrospective comparison with Glucksberg grade. *British Journal of Haematology*, **97**, 855–864.
- Roy, J., Snover, D., Weisdorf, S., Mulvahill, A., Filipovich, A. & Weisdorf, D. (1991) Simultaneous upper and lower endoscopic biopsy in the diagnosis of intestinal graft-versus-host disease. *Transplantation*, **51**, 642–646.
- Roy, J., McGlave, P.B., Filipovich, A.H., Miller, W. J., Bazar, B.R., Ramsay, N.K., Kersey, J.H. & Weisdorf, D.J. (1992) Acute graft-versus-host disease following unrelated donor marrow transplantation: failure of conventional therapy. *Bone Marrow Transplantation*, **10**, 77–82.
- Saliba, R.M., de Lima, M., Giral, S., Andersson, B., Khouri, I.F., Hosing, C., Ghosh, S., Neumann, J., Hsu, Y., De Jesus, J., Qazilbash, M.H., Champlin, R.E. & Couriel, D.R. (2007) Hyperacute GvHD: risk factors, outcomes, and clinical implications. *Blood*, **109**, 2751–2758.
- Schmidt-Hieber, M., Fietz, T., Knauf, W., Uharek, L., Hopfenmüller, W., Thiel, E. & Blau, I.W. (2005) Efficacy of the interleukin-2 receptor antagonist basiliximab in steroid-refractory acute graft-versus-host disease. *British Journal of Haematology*, **130**, 568–574.
- Schnitzler, M., Hasskarl, J., Egger, M., Bertz, H. & Finke, J. (2009) Successful treatment of severe acute intestinal graft-versus-host disease resistant to systemic and topical steroids with alemtuzumab. *Biology of Blood and Marrow Transplantation*, **15**, 910–918.
- Shaughnessy, P.J., Bachier, C., Grimley, M., Freytes, C.O., Callander, N.S., Essell, J.H., Flomenberg, N., Selby, G. & Lemaistre, C.F. (2005) Denileukin difitox for the treatment of steroid-resistant acute graft-versus-host disease. *Biology of Blood and Marrow Transplantation*, **11**, 188–193.
- Sieper, J. & Van Den Brande, J. (2005) Diverse effects of infliximab and etanercept on T lymphocytes. *Seminars in Arthritis and Rheumatism*, **34**, 23–27.
- Smith, E.P., Sniecinski, I., Dagens, A.C., Parker, P. M., Snyder, D.S., Stein, A.S., Nademanee, A., O'Donnell, M.R., Molina, A., Schmidt, G.M., Stepan, D.E., Kapoor, N., Niland, J.C. & Forman, S.J. (1998) Extracorporeal photochemotherapy for treatment of drug-resistant graft-versus-host disease. *Biology of Blood and Marrow Transplantation*, **4**, 27–37.
- Snover, D.C., Weisdorf, S.A., Ramsay, N.K., McGlave, P. & Kersey, J.H. (1984) Hepatic GvHD: a study of the predictive value of liver biopsy in diagnosis. *Hepatology*, **4**, 123–130.
- Snover, D.C., Weisdorf, S.A., Vercellotti, G.M., Rank, B., Hutton, S. & McGlave, P. (1985) A histopathologic study of gastric and small intestinal graft-versus-host disease following allogeneic bone marrow transplantation. *Human Pathology*, **16**, 387–392.
- Srinivasan, R., Chakrabarti, S., Walsh, T., Igarashi, T., Takahashi, Y., Kleiner, D., Donohue, T., Shalabi, R., Carvallo, C., Barrett, A.J., Geller, N. & Childs, R. (2004) Improved survival in steroid-refractory aGvHD after non-myeloablative allogeneic transplantation using a daclizumab-based strategy with comprehensive infection prophylaxis. *British Journal of Haematology*, **124**, 777–786.
- Stelljes, M., Hermann, S., Albring, J., Köhler, G., Löffler, M., Franzius, C., Poremba, C., Schlösser, V., Volkmann, S., Opitz, C., Bremer, C., Kucharzik, T., Silling, G., Schober, O., Berdel, W. E., Schäfers, M. & Kienast, J. (2008) Clinical molecular imaging in intestinal graft-versus-host disease: mapping of disease activity, prediction, and monitoring of treatment efficiency by positron emission tomography. *Blood*, **111**, 2909–2918.
- Strasser, S.I., Shulman, H.M., Flowers, M.E., Reddy, R., Margolis, D.A., Prumbaum, M., Seropian, S.E. & McDonald, G.B. (2000) Chronic

- graft-versus-host disease of the liver: presentation as an acute hepatitis. *Hepatology*, **32**, 1265–1271.
- Sullivan, K.M. (2004) Graft-vs-host disease. In: Thomas' Haematopoietic Cell Transplantation (ed. by K.G. Blume, S.J. Forman & F.R. Appelbaum), pp. 635–664. Blackwell Publishing Ltd, Oxford, UK.
- Takami, A., Mochizuki, K., Okumura, H., Ito, S., Suga, Y., Yamazaki, H., Yamazaki, M., Kondo, Y., Asakura, H. & Nakao, S. (2006) Mycophenolate mofetil is effective and well tolerated in the treatment of refractory acute and chronic graft-versus-host disease. *International Journal of Hematology*, **83**, 80–85.
- Trzonkowski, P., Bieniaszewska, M., Juścińska, J., Dobyszk, A., Krzystyniak, A., Marek, N., Mysliwska, J. & Hellmann, A. (2009) First-in-man clinical results of the treatment of patients with GvHD with human ex vivo expanded CD4+CD25+CD127– T regulatory cells. *Clinical Immunology*, **133**, 22–26.
- Uberti, J.P., Ayash, L., Ratanatharathorn, V., Silver, S., Reynolds, C., Becker, M., Reddy, P., Cooke, K.R., Yanik, G., Whitfield, J., Jones, D., Hutchinson, R., Braun, T., Ferrara, J.L. & Levine, J.E. (2005) Pilot trial on the use of etanercept and methylprednisolone as primary treatment for acute graft-versus-host disease. *Biology of Blood and Marrow Transplantation*, **11**, 680–687.
- Van Lint, M.T., Uderzo, C., Locasciulli, A., Majolino, I., Scimè, R., Locatelli, F., Giorgiani, G., Arcese, W., Iori, A.P., Falda, M., Bosi, A., Miniero, R., Alessandrino, P., Dini, G., Rotoli, B. & Bacigalupo, A. (1998) Early treatment of acute graft-versus-host disease with high- or low-dose 6-methylprednisolone: a multicenter randomized trial from the Italian Group for Bone Marrow Transplantation. *Blood*, **92**, 2288–2293.
- Van Lint, M.T., Milone, G., Leotta, S., Uderzo, C., Scimè, R., Dallorso, S., Locasciulli, A., Guidi, S., Mordini, N., Sica, S., Cudillo, L., Fagioli, F., Selleri, C., Bruno, B., Arcese, W. & Bacigalupo, A. (2006) Treatment of acute graft-versus-host disease with prednisolone: significant survival advantage for day + 5 responders and no advantage for nonresponders receiving anti-thymocyte globulin. *Blood*, **107**, 4177–4181.
- Varadi, G., Or, R., Slavin, S. & Nagler, A. (1996) In vivo CAMPATH-1 monoclonal antibodies: a novel mode of therapy for acute graft-versus-host disease. *American Journal of Hematology*, **52**, 236–237.
- Vogelsang, G.B., Lee, L. & Bensen-Kennedy, D.M. (2003) Pathogenesis and treatment of graft-versus-host disease after bone marrow transplant. *Annual Review of Medicine*, **54**, 29–52.
- Wandroo, F., Auguston, B., Cook, M., Craddock, C. & Mahendra, P. (2004) Successful use of Campath-1H in the treatment of steroid refractory liver GvHD. *Bone Marrow Transplantation*, **34**, 285–287.
- Wang, J.Z., Liu, K.Y., Xu, L.P., Liu, D.H., Chen, Y. H. & Huang, X.J. (2008) Chimeric anti-CD25 monoclonal antibody for treating acute graft-versus-host disease after allogeneic hematopoietic stem cell transplantation. *Zhonghua Nei Ke Za Zhi*, **47**, 923–925.
- Wang, J.Z., Liu, K.Y., Xu, L.P., Liu, D.H., Han, W., Chen, H., Chen, Y.H., Zhang, X.H., Zhao, T., Wang, Y. & Huang, X.J. (2011a) Basiliximab for the treatment of steroid-refractory acute graft-versus-host disease after unmanipulated HLA-mismatched/haploidentical hematopoietic stem cell transplantation. *Transplant Proceedings*, **43**, 1928–1933.
- Wang, Y., Xu, L.P., Liu, K.Y., Liu, D.H., Wang, J., Chen, H., Chen, Y.H., Han, W. & Huang, X.J. (2011b) Low-dose MTX combined with low-dose methylprednisolone as a first-line therapy for the treatment of aGvHD: safety and feasibility. *Bone Marrow Transplantation*, **46**, 892–898.
- Weintraub, J.L., Belanger, A.R., Sung, C.C., Stangl, P.A., Nowakowski, F.S. & Lookstein, R.L. (2010) Intra-arterial methylprednisolone infusion in treatment-resistant graft-versus-host disease. *Cardiovascular Interventional Radiology*, **33**, 509–512.
- Weisdorf, D., Haake, R., Blazar, B., Miller, W., McGlave, P., Ramsay, N., Kersey, J. & Filipovich, A. (1990) Treatment of moderate/severe acute graft-versus-host disease after allogeneic bone marrow transplantation: an analysis of clinical risk features and outcome. *Blood*, **75**, 1024–1030.
- Wolff, D., Roessler, V., Steiner, B., Wilhelm, S., Weirich, V., Brenmoehl, J., Leithaeuser, M., Hofmeister, N., Junghans, C., Casper, J., Hartung, G., Holler, E. & Freund, M. (2005) Treatment of steroid-resistant acute graft-versus-host disease with daclizumab and etanercept. *Bone Marrow Transplantation*, **35**, 1003–1010.
- Wolff, D., Schleuning, M., von Harsdorf, S., Bachner, U., Gerbitz, A., Stadler, M., Ayuk, F., Kiani, A., Schwerdtfeger, R., Vogelsang, G.B., Kobbe, G., Gramatzki, M., Lawitschka, A., Mohty, M., Pavletic, S.Z., Greinix, H. & Holler, E. (2011) Consensus conference on clinical practice in chronic GVHD: second-line treatment of chronic graft-versus-host disease. *Biology of Blood and Marrow Transplantation*, **17**, 1–17.
- Zhou, Y., Barnett, M.J. & Rivers, J.K. (2000) Clinical significance of skin biopsies in the diagnosis and management of graft-vs-host disease in early postallogeic bone marrow transplantation. *Archives of Dermatology*, **136**, 717–721.
- Zidan, H., Lo, S., Wiebe, D., Talano, J. & Alemzadeh, R. (2008) Severe hypercholesterolemia mediated by lipoprotein X in a pediatric patient with chronic graft-versus-host disease of the liver. *Pediatric Blood Cancer*, **50**, 1280–1281.